

PARASITIC DINOFLAGELLATES IN MEDITERRANEAN ZOOPLANKTON

Alf Skovgaard* and Enric Saiz

Institut de Ciències del Mar (CMIMA - CSIC), Barcelona, Catalunya, Spain - * skovgaard@icm.csic.es, enric@icm.csic.es

Abstract

We investigated the occurrence of parasitic dinoflagellates in zooplankton (copepods and appendicularians) off Barcelona, Spain. The most common species were the intestinal parasites *Blastodinium* spp. found in the copepod genera *Oncaea*, *Corycaeus*, *Oithona* and *Paracalanus*. However, also the coelomic parasite *Syndinium* was relatively common in *Paracalanus*. The ectoparasite *Oodinium pouchetii* occasionally infested large proportions of appendicularians.

Keywords: *Dinoflagellate, Parasite, Copepod, Blastodinium, Syndinium*

A number of dinoflagellates are parasites of marine zooplankton organisms (1) and, at times, these parasites may contribute significantly to the mortality of copepod populations (2, 3). However, the profusion of parasitism and its impact on zooplankton population dynamics has received little attention and is not very well understood.

To study the prevalence and possible impact of dinoflagellate parasites, we collected zooplankton weekly or biweekly off Port Olímpic, Barcelona, by taking vertical net tows with 53 and 100 µm plankton nets. Live animals were observed qualitatively within 2-5 hours after sampling and, in addition, samples fixed in formaldehyde were studied quantitatively for the prevalence of parasitized zooplankton organisms.

Blastodinium spp. could be detected in live copepods as large greenish or brownish bodies in the gut of infected animals (Figs 1-3). In fixed animals, infection with *Blastodinium* was less evident due to the lack of colour as a diagnostic tool. Based on the host species and the size and shape of the parasites (1), we were able to identify at least 3 *Blastodinium* species: *B. mangini* Chatton (including the variety *B.*

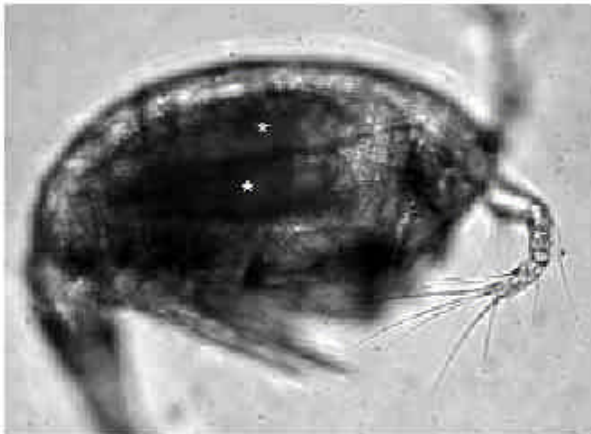

Fig. 1. *Oncaea* sp. female infected with two individuals of *Blastodinium mangini* v. *oncaea* (asterisks). Live specimen.



Fig. 2. *Paracalanus parvus* female infected with *Blastodinium contortum*. Live specimen.

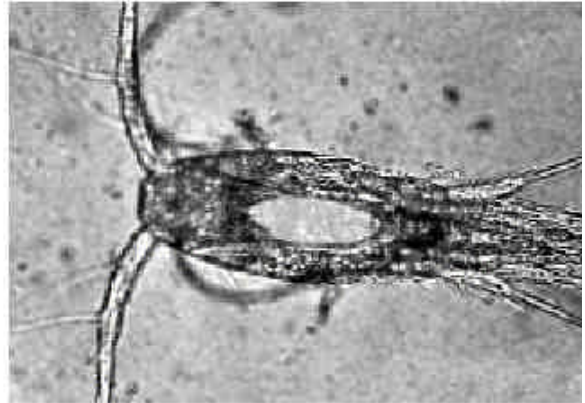


Fig. 3. *Oithona nana* infected with *Blastodinium oviforme*. Live specimen viewed in epifluorescent light. Fluorescence of *Blastodinium* chlorophyll seen as bright body

mangini v. *oncaea* Chatton), *B. contortum* Chatton and *B. oviforme* Chatton. *Syndinium turbo* Chatton could be detected equally well in live and fixed animals (*P. parvus*) since this parasite made its host conspicuously dilated, dark and opaque (2, 3). The detection of *Oodinium appendicularians* was straightforward, since these are ectoparasites and form characteristic cysts attached the epithelium of the host. When infected copepods were kept in seawater in the laboratory, sporulation always occurred within 1-2 days and free-swimming parasite zoospores could then be observed. This indicates that only the final developmental stages of the parasite life cycles within its copepod hosts were detected. New methods, therefore, need to be applied in order to gain more knowledge on the total infection frequencies and, thereby, the effect of dinoflagellate parasites on their copepod hosts.

References

- 1-Chatton, È., 1920. Les Péridiniens parasites: morphologie, reproduction, éthologie. Arch. Zool. Exp. Gen., 59: 1-475.
- 2-Ianora, A., Scotto di Carlo, B., Mazzocchi, M. G., and Mascellaro, P., 1990. Histomorphological changes in the reproductive condition of parasitized marine planktonic copepods. J. Plank. Res., 12: 249-258.
- 3-Kimmerer, W. J., and McKinnon, A. D., 1990. High mortality in a copepod population caused by a parasitic dinoflagellate. Mar. Biol., 107: 449-452.